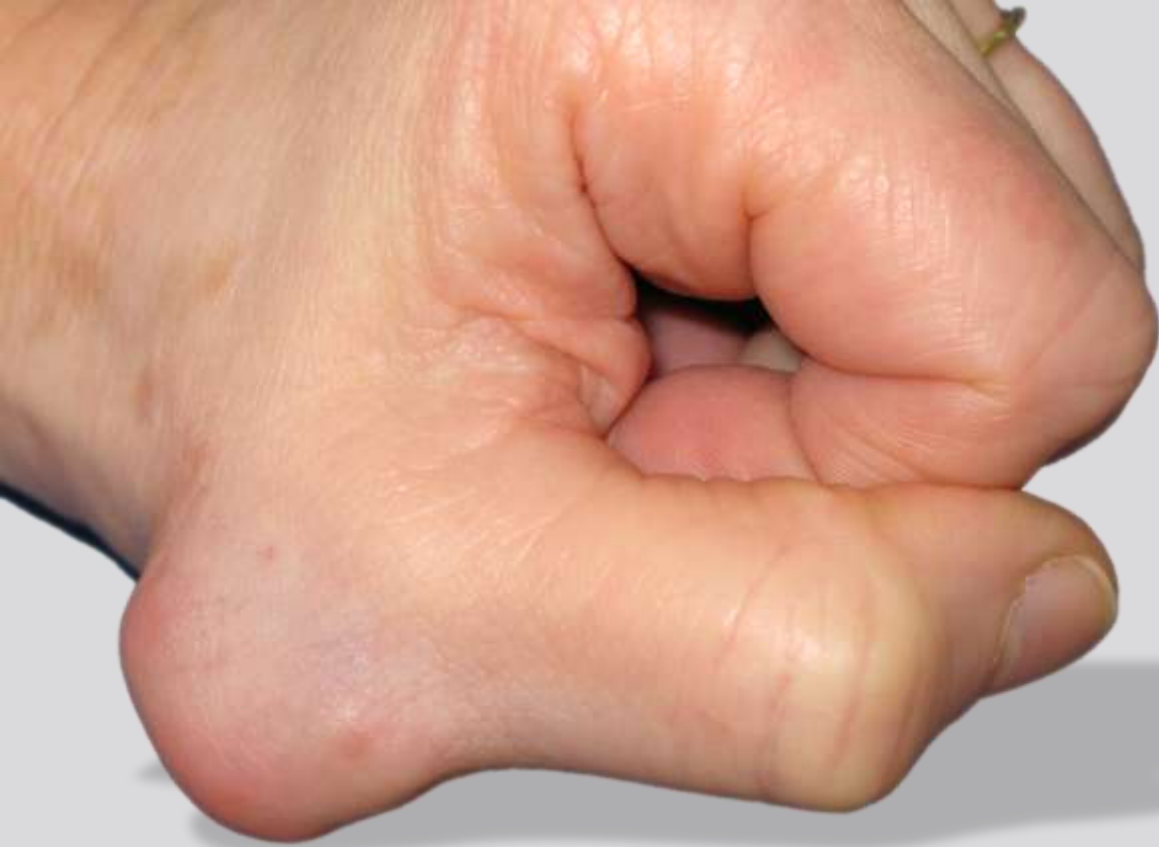
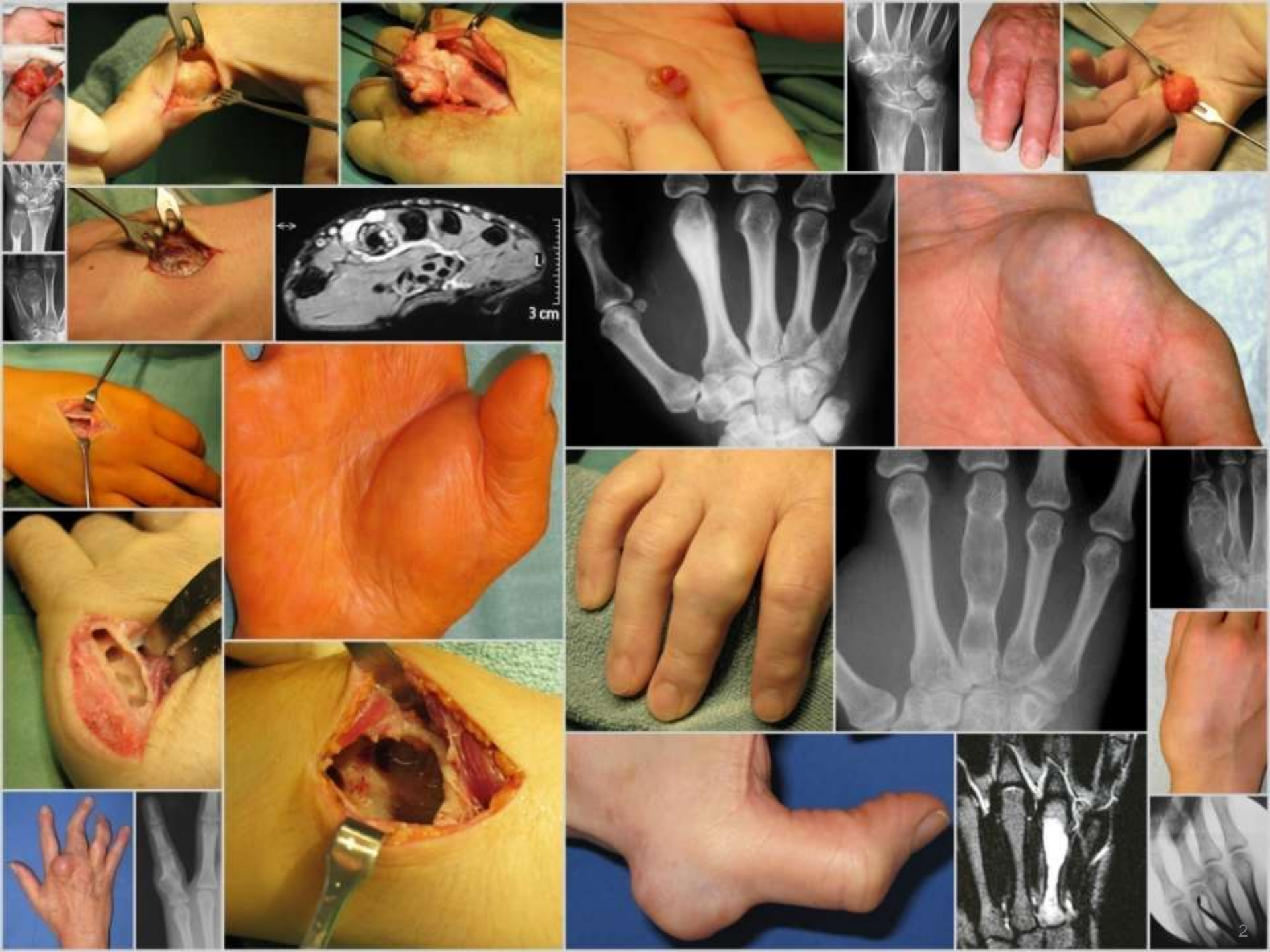


Tumours of the hand

F. Machacek, U. Schwarzinger, P. Ritschl
Gersthof Orthopaedic Hospital, Vienna



tumours of the hand: relative frequency

**location:
hand / wrist**

- **bone tumours:**
 - malignant bone tumours
- **soft tissue tumours:**
 - malignant soft tissue sarcoma:

4-6 %
1,2 %

Besser 1987
Campbell 1995
Campanacci 1999

~ 11%
3-4 %

Kransdorf 1995
Campanacci 1981
McPhee 1999

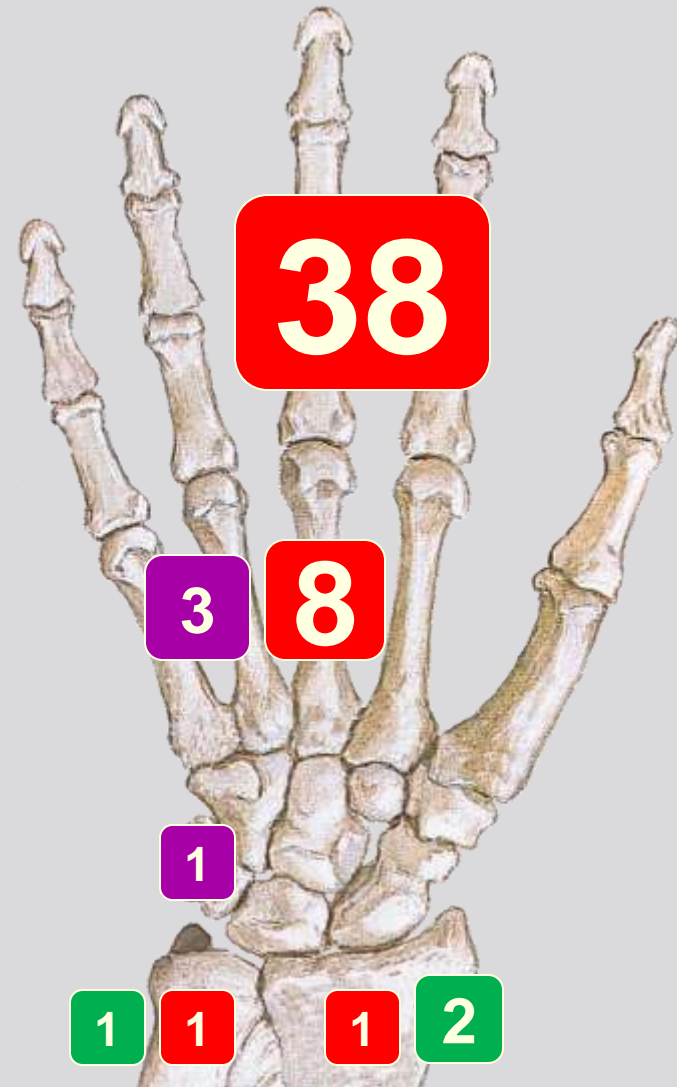
epidemiology

- tumours of the hand from 1994 to 2009
 - typical non-neoplastic lesions excluded (ganglion cyst, ...)
- 142 patients
 - ♂:♀ 57:85
 - age: Ø 41 yrs. (8-85)

	bone	soft tissue	total
benign	70	52	122
malignant	16	4	20
total	86	56	142

benign bone tumours (n=70)

chondroma	48
osteoid-osteoma	4
giant cell tumour	3
osteoblastoma	2
osteochondroma	2
aneurysmatic bone cyst	2
solitary bone cyst	2
periosteal chondroma	2
others	5

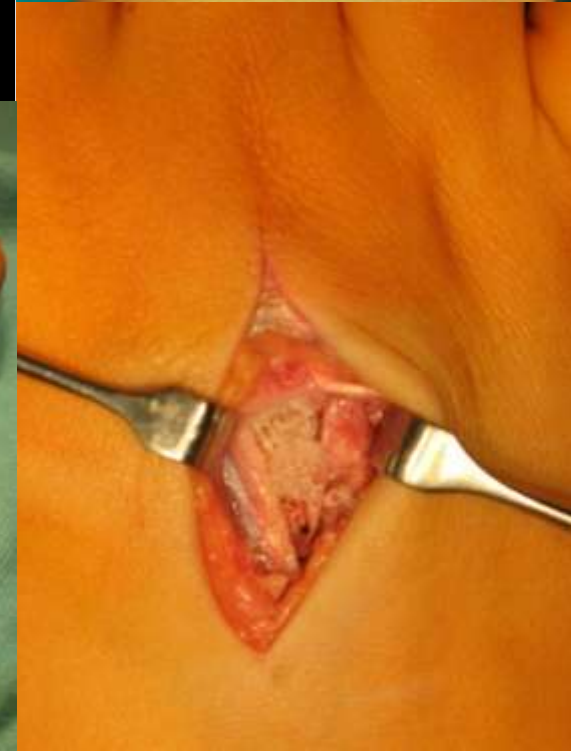
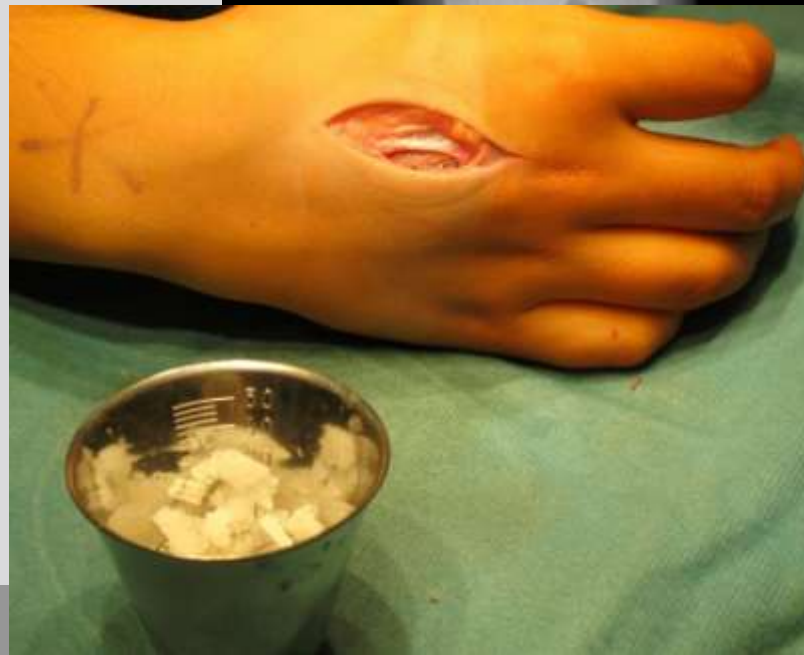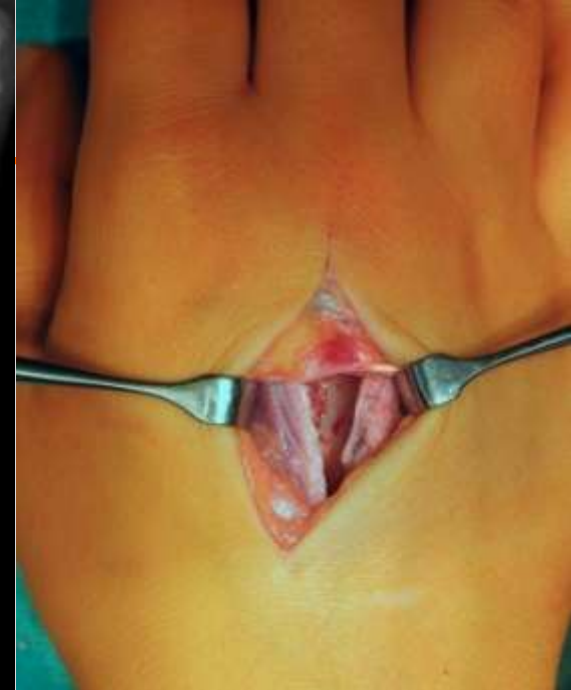

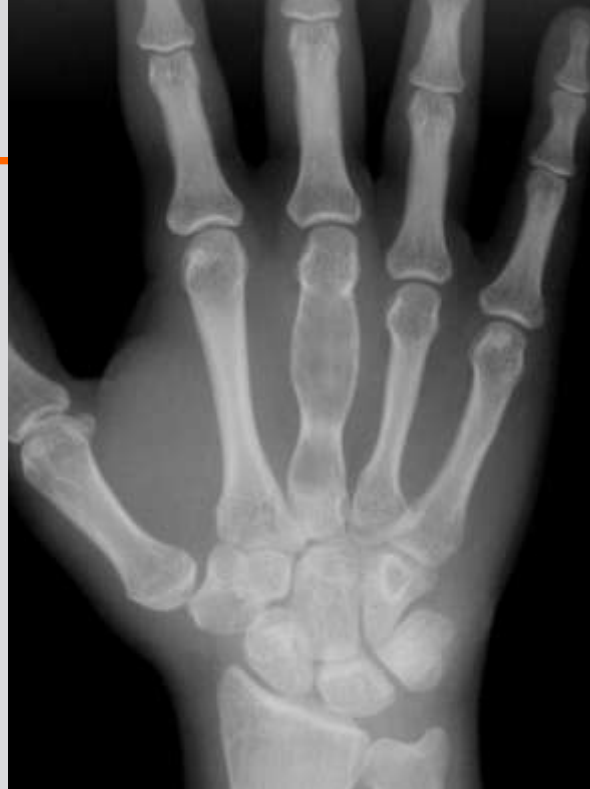
pat. 18 yrs.

chondroma

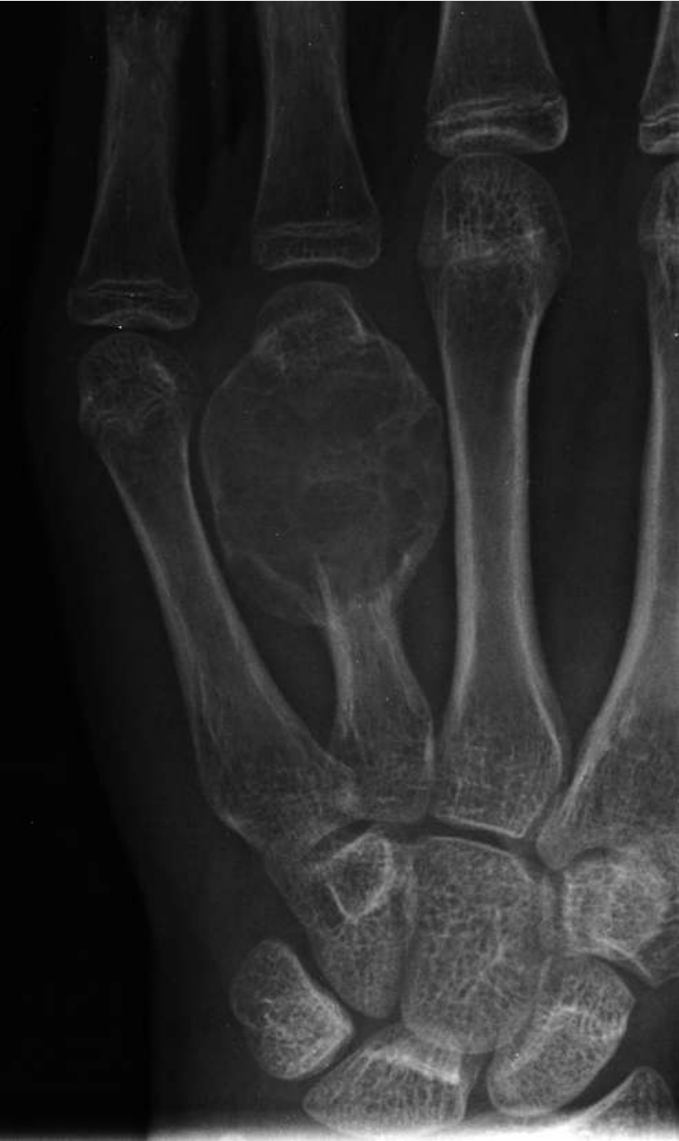standard procedure:

- curettage
- ball bur
- homologous bone grafting

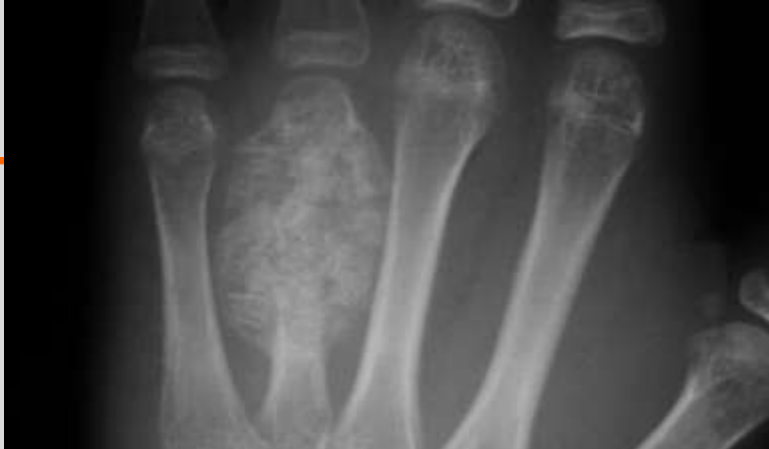

pat. 15 yrs.

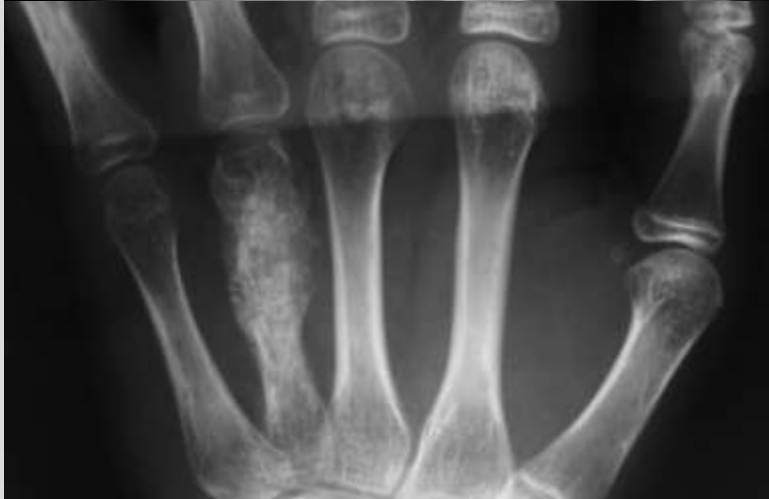aneurysmatic bone cyst



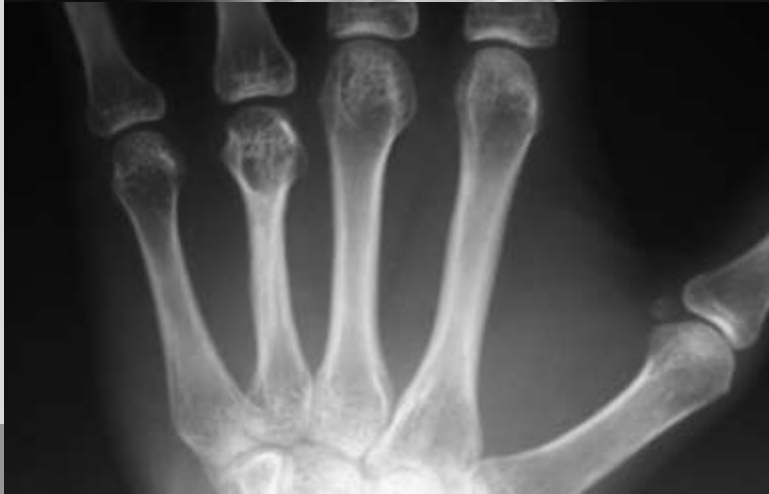postop



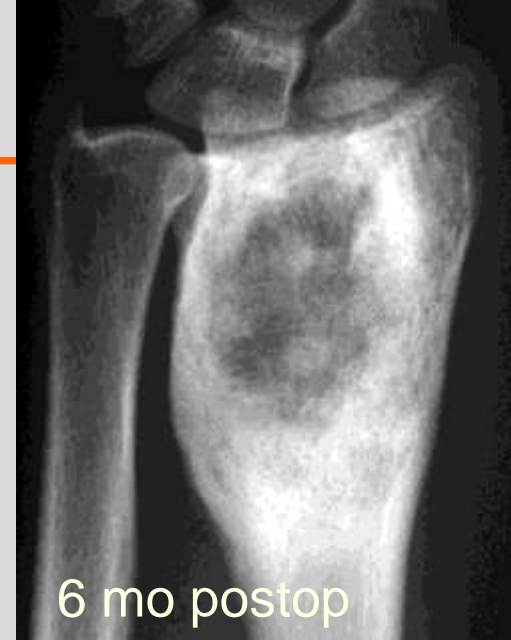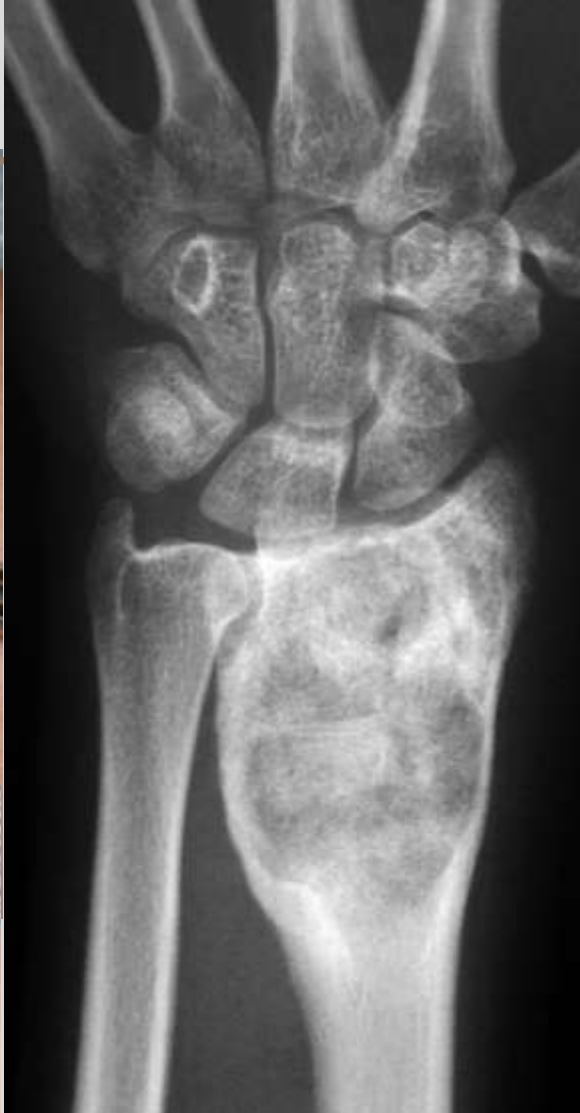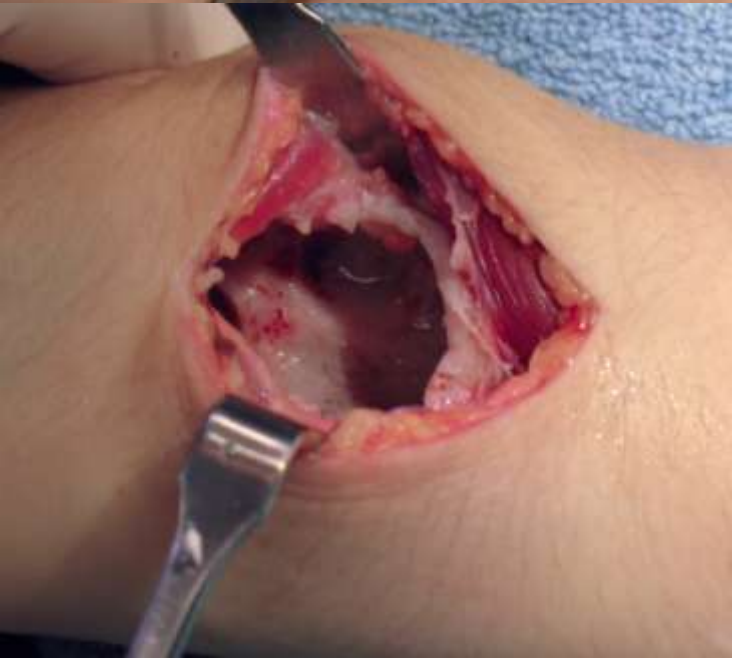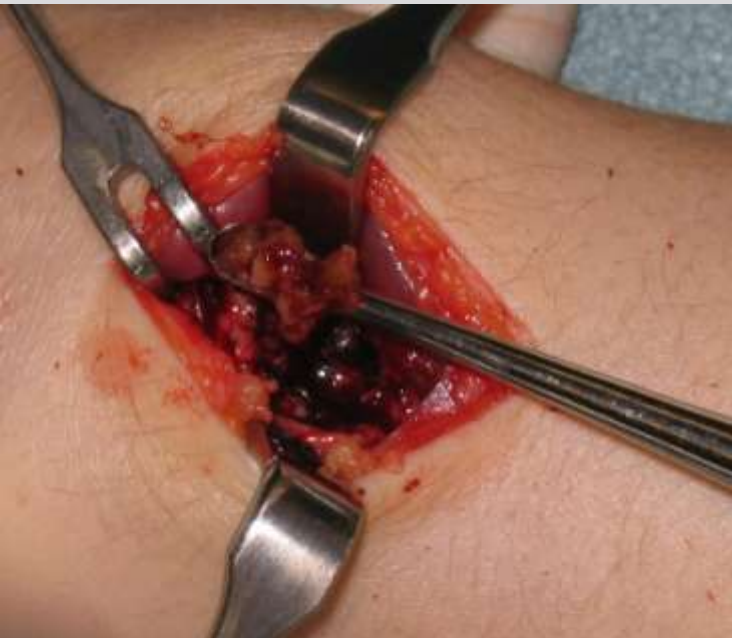4 mo
postop



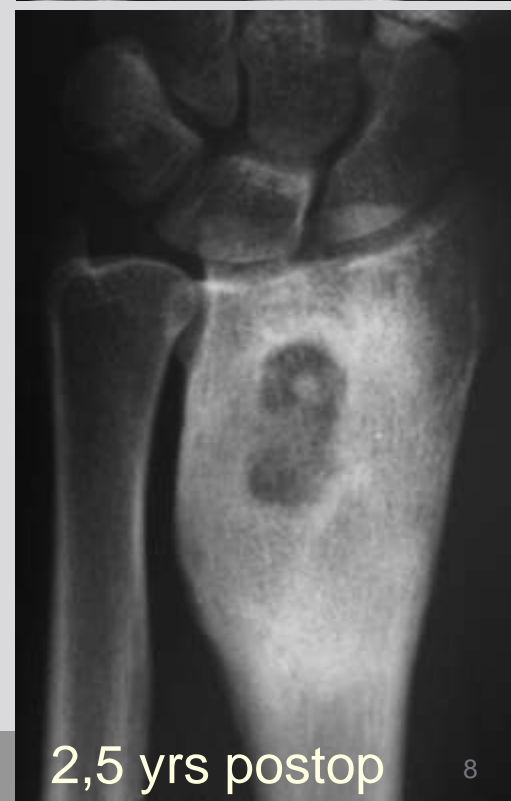2,5 yrs
postop



pat. 31 yrs.



6 mo postop



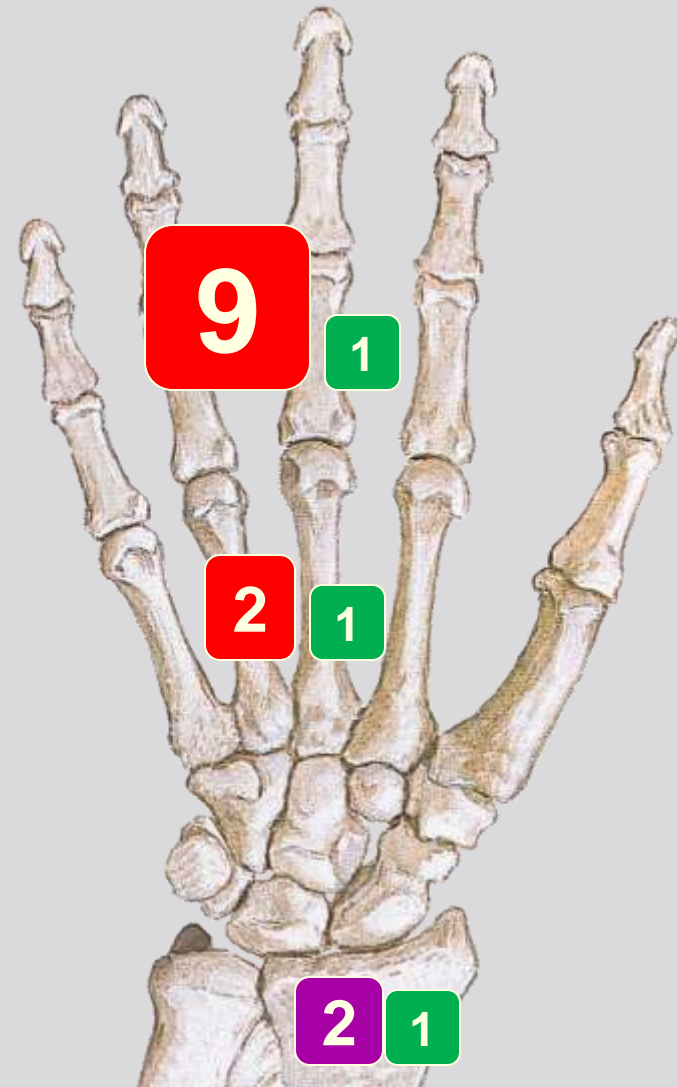
2,5 yrs postop

giant cell tumour

malignant bone tumours

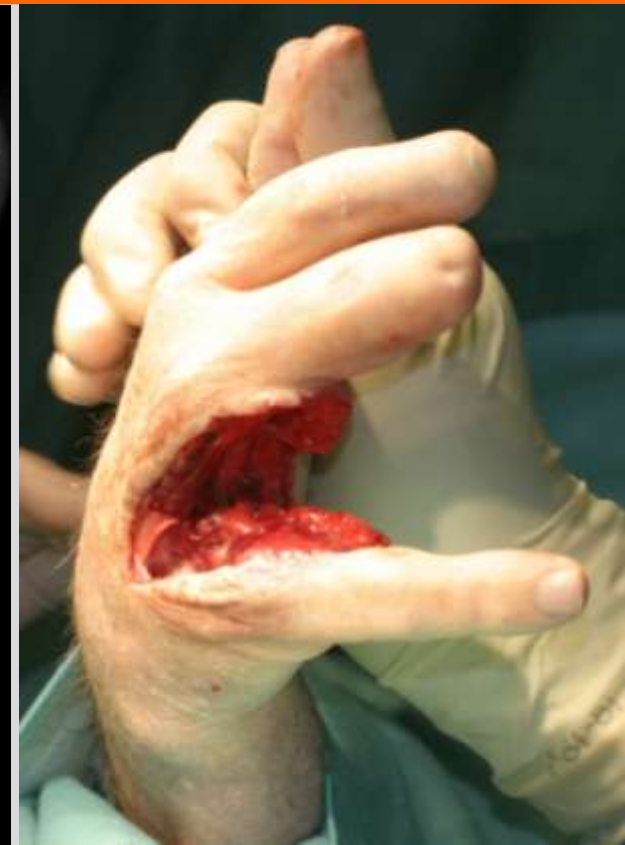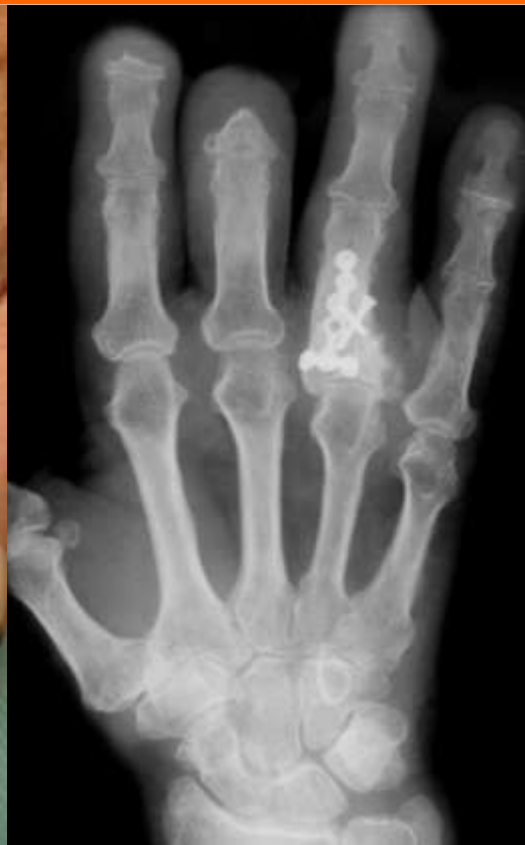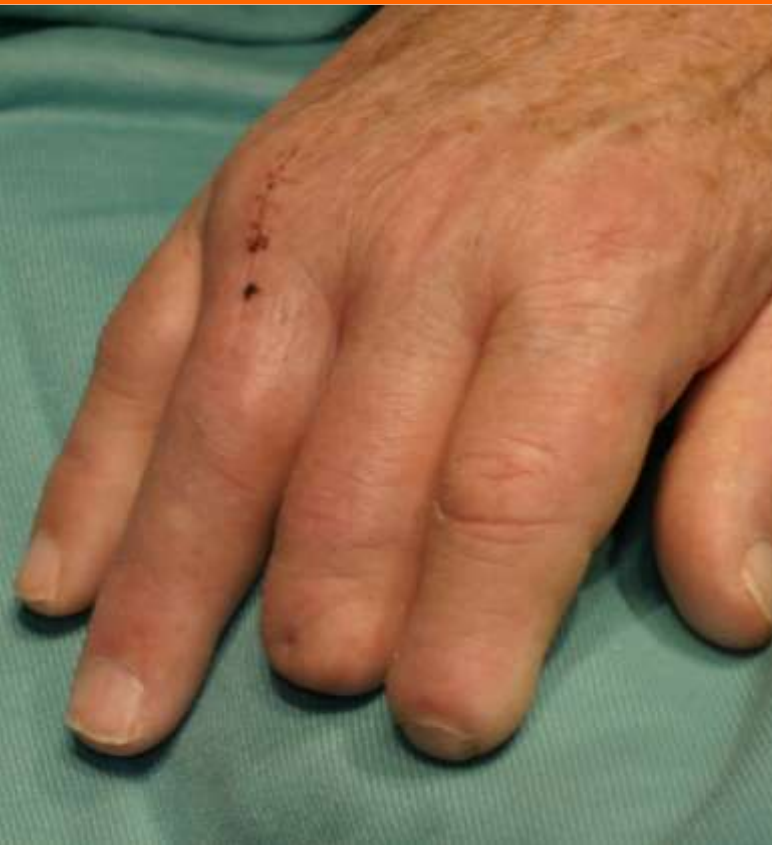(n=16)

chondrosarcoma	11
osteosarcoma	2
metastasis	3

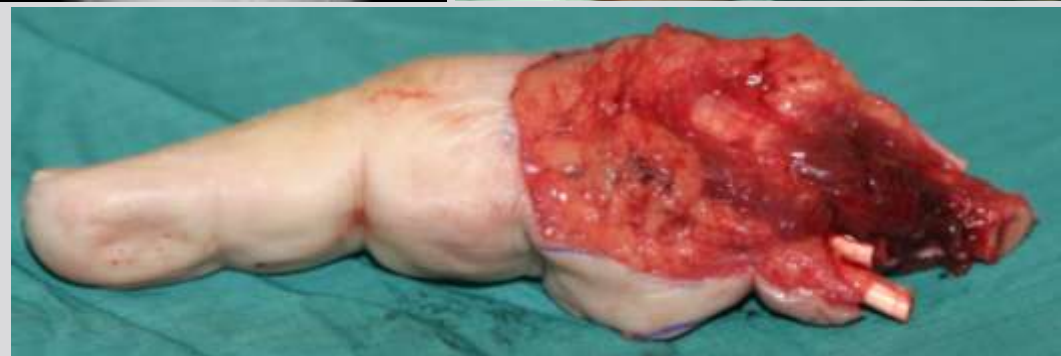

pat. 79 yrs.

chondrosarcoma G2 dig IV

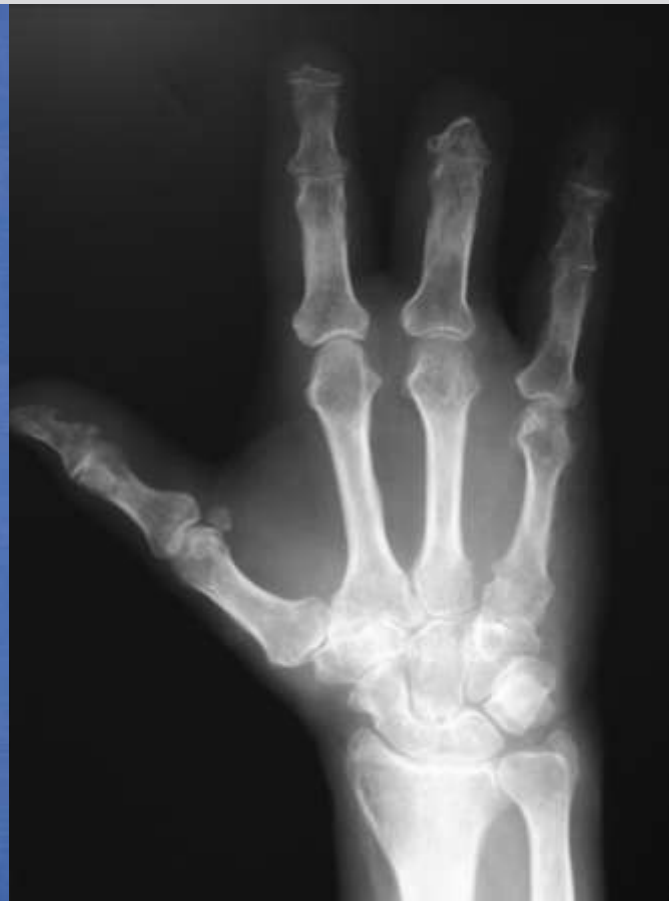
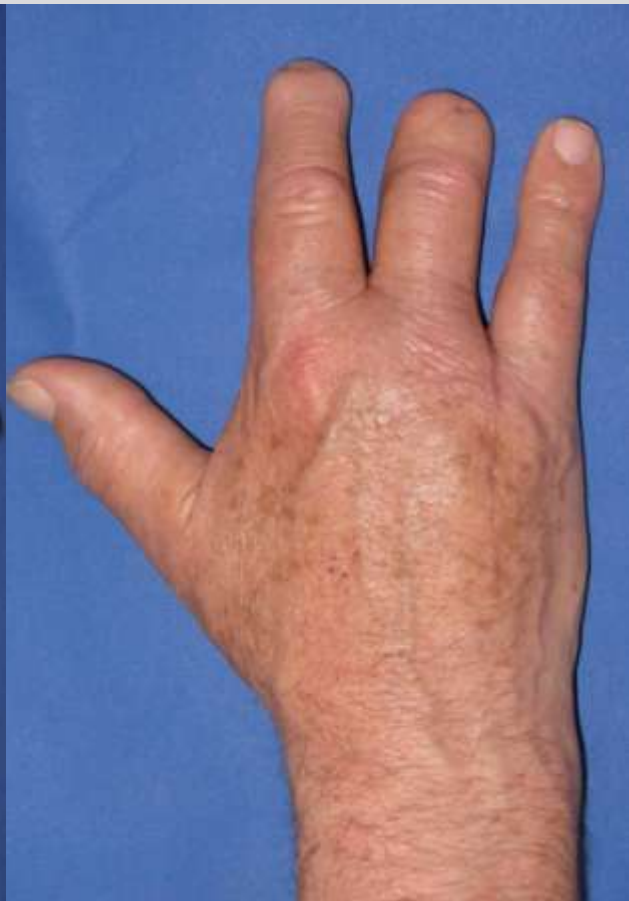
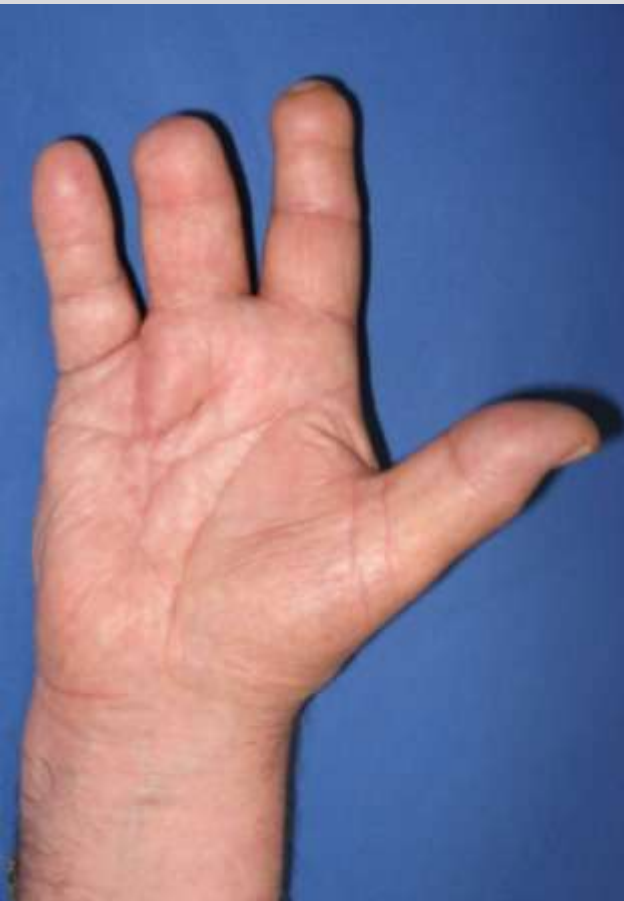procedure: wide amputation



pat. 79 yrs.

chondrosarcoma G2 dig IV



benign soft tissue tumours (n=52)

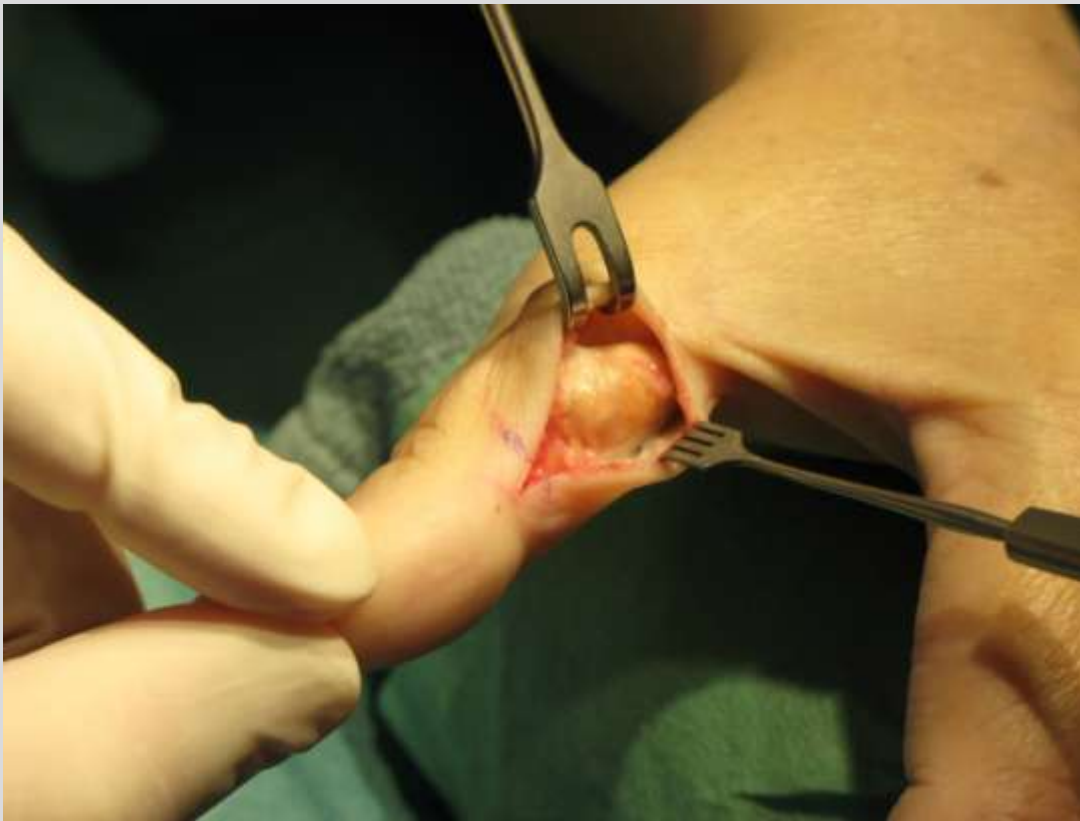PVNS	32
hemangioma	6
fibrolipoma	4
lipoma	2
others	6



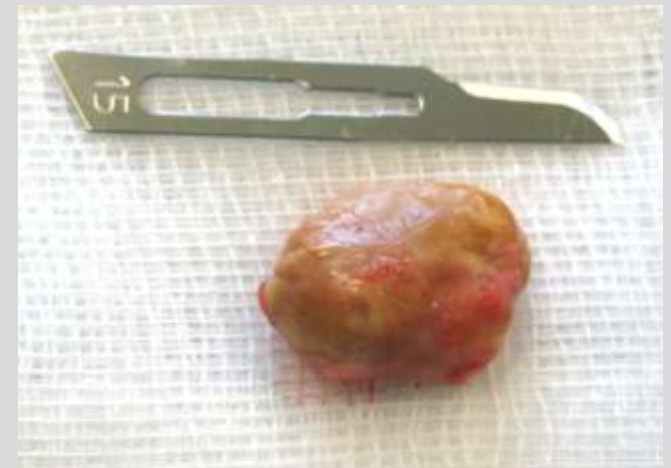pat. 55 yrs.

Giant cell tumour of the tendon sheath

syn.: **P**igmented **V**illo-**N**odular **S**ynovitis (PVNS)



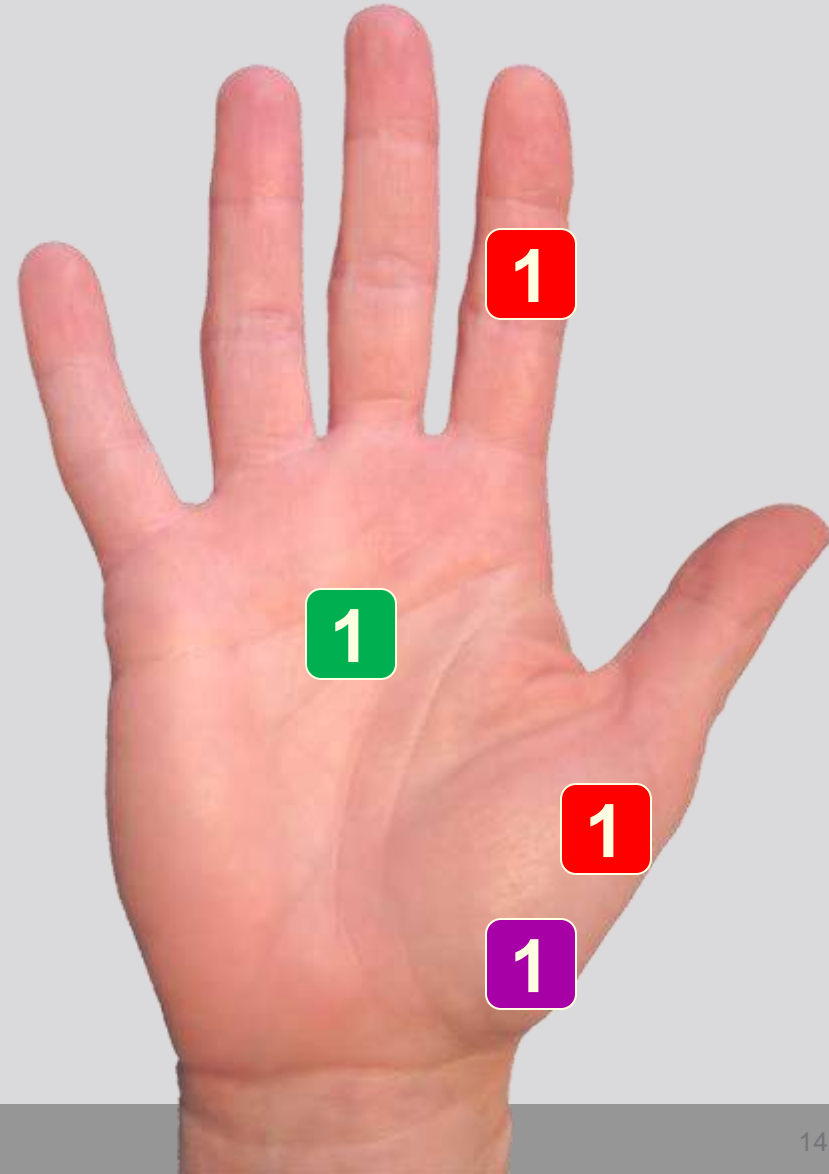
procedure:
marginal resection



malignant soft tissue tumours

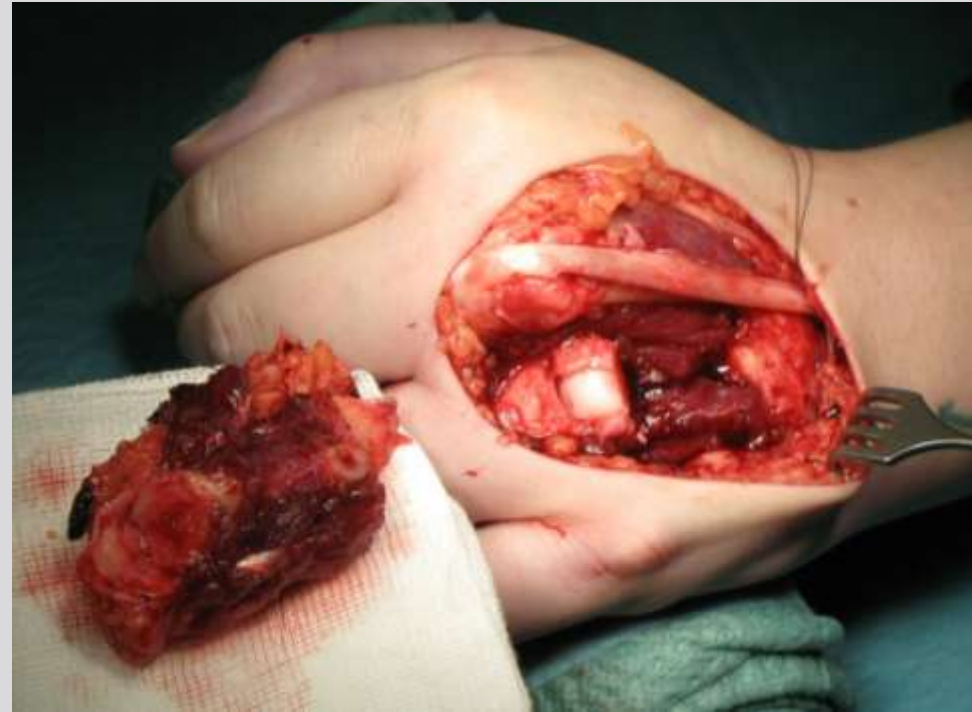
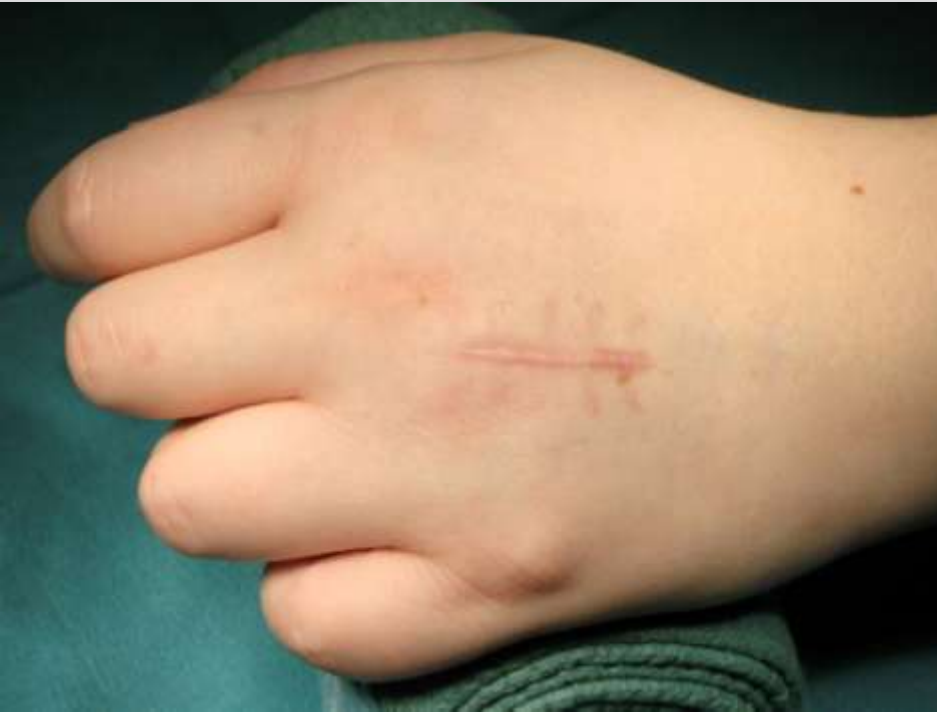(n=4)

synovial sarcoma	2
Ewing sarcoma	1
extraoss. myxoid chondrosarcoma	1



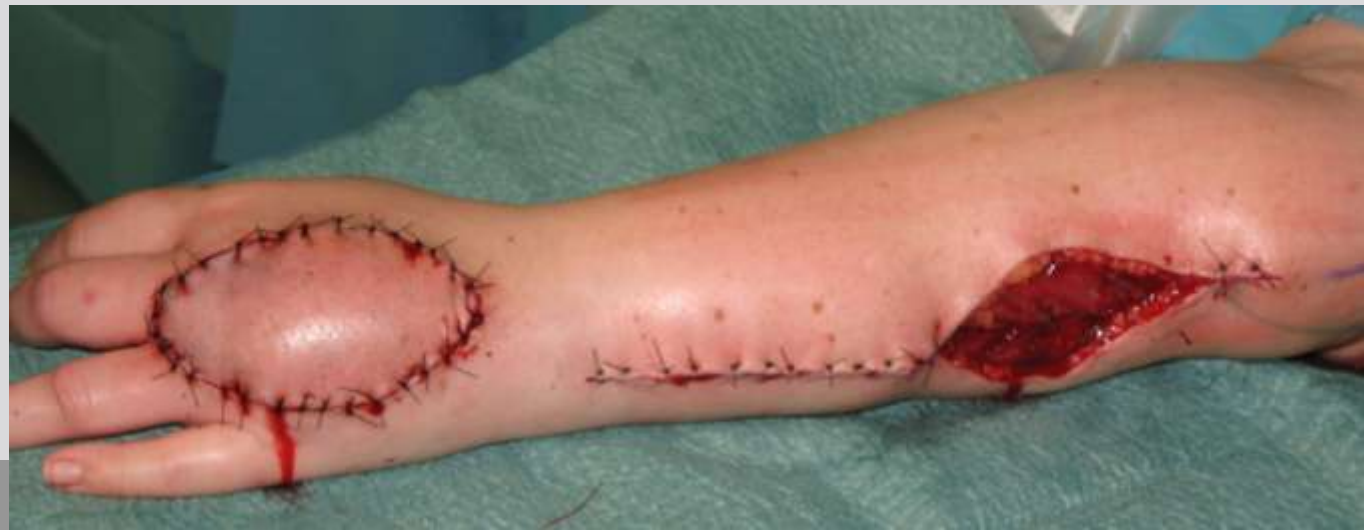pat. 28 yrs.

extraosseous myxoid chondrosarcoma



procedure:

- wide resection
- radialis flap
- iliac bone graft

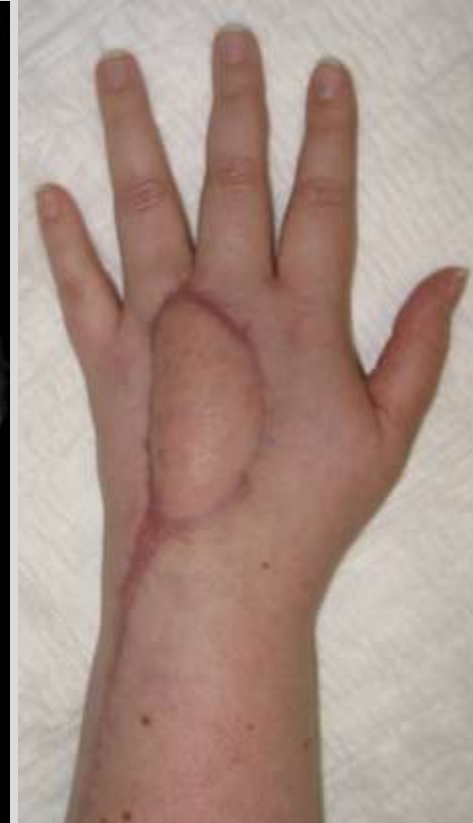
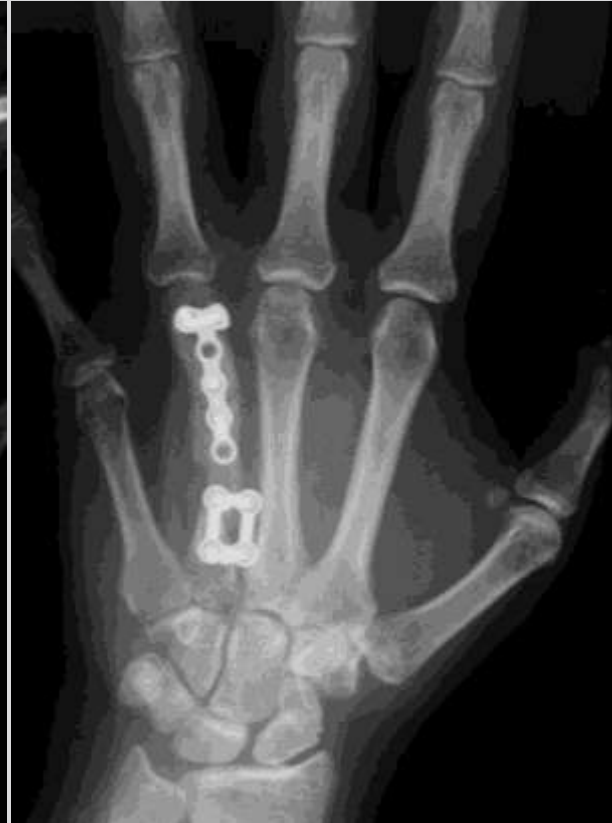
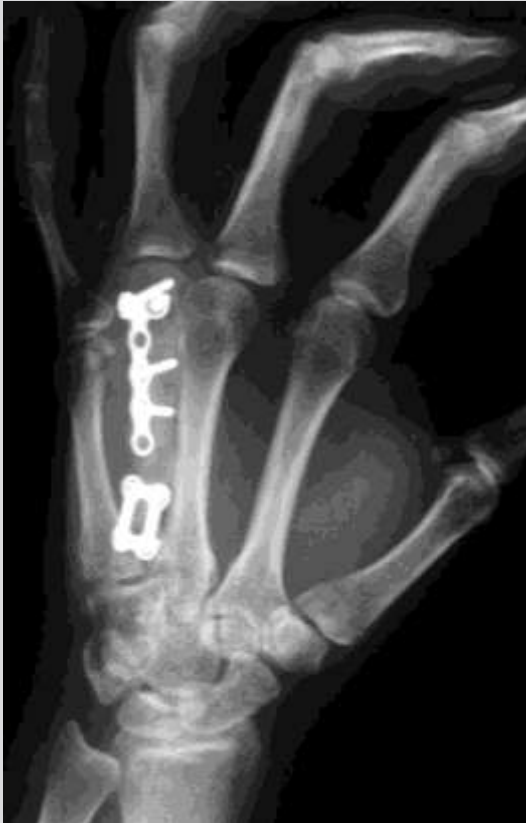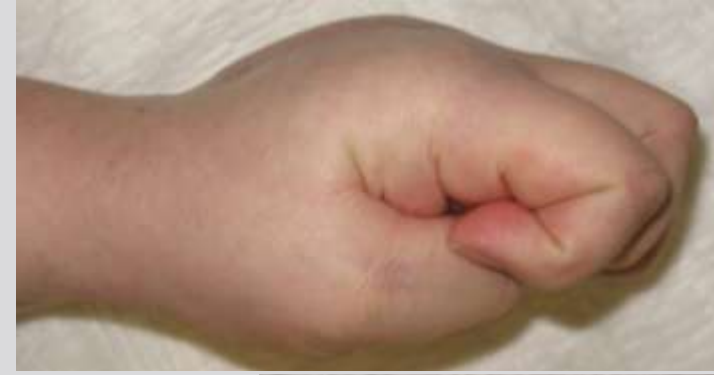pat. 28 yrs.

extraosseous myxoid chondrosarcoma

procedure:

- wide resection
- radialis flap
- iliac bone graft



follow up of malignant cases (n=19)

- no contact 3
- deceased (3 - 4 mo postop) 2

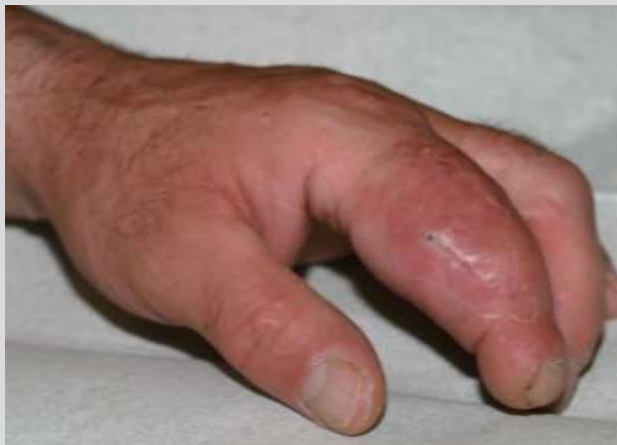- **alive with oncological status 14**

follow up 5,2 years (10 mo-14 yrs)

no evidence of disease (NED) 12

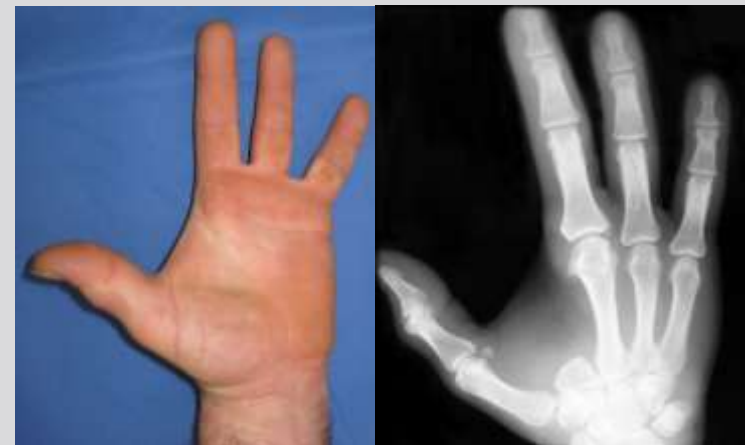radiotherapy only (AWD) 2

Quick DASH score (12/14): 9.6 (0-24.9)



chondrosarcoma G2
index finger

follow up
4 yrs. postop





thank you